

CASE REPORT

Myoepithelioma of the Hard Palate: A Rare Case Report

¹Kunal Advani, ²Nikhil Diwan, ³Ashwini Pai, ⁴CM Kadam, ⁵Rashmi Sapkal, ⁶Narayani Deshpande, ⁷Mahesh Chavan

ABSTRACT

Myoepithelioma is a rare benign tumor which represents about 1.5% of all the salivary gland tumors. The most common site of involvement is parotid gland, followed by the palate in the oral cavity. Clinically, its presentation may resemble pleomorphic adenoma. In this report, we present a case of 48-year-old male patient who reported with a painless swelling in the hard palate in the left premolar and molar region since 4 months. Histopathological examination of the biopsied specimen indicated a diagnosis of spindle cell myoepithelioma. This report aims to highlight the clinical, radiological and histopathological features, and the probable differential diagnosis of this rare tumor.

Keywords: Benign tumor, Myoepithelioma, Palate, Salivary gland neoplasm, Spindle cell.

How to cite this article: Advani K, Diwan N, Pai A, Kadam CM, Sapkal R, Deshpande N, Chavan M. Myoepithelioma of the Hard Palate: A Rare Case Report. *Int J Oral Care Res* 2017;5(3): 260-263.

Source of support: Nil

Conflict of interest: None

INTRODUCTION

Myoepithelioma, also known as myoepithelial adenoma and benign myoepithelial tumor, is a rare tumor of oral cavity. It derives its name by the fact that it is mainly constituted by ectodermally derived contractile cells that act as smooth muscle cells and are named myoepithelial cells (MEC).

Myoepithelial cells are seen in many secretory organs including salivary glands. Sheldon, in 1943, was the first to identify myoepithelial tumors as a distinct salivary gland tumor entity. In the oral cavity, anterior part of the hard palate is devoid of salivary glands, hence myoepithelioma occurs in the posterolateral part of the hard

palate and soft palate.¹ They present as asymptomatic slow growing masses over a period of a few months to years. Here, we present a rare case of myoepithelioma of the hard palate along with their imaging features, histological findings, and differential diagnosis.

CASE REPORT

A 48-year-old male patient reported to the Department of Oral Medicine and Radiology, with a complaint of painless swelling on the hard palate since 4 months. The swelling was initially smaller in size which gradually increased to the present size. He also gave a history of thermal burn in the region due to which an ulceration was seen at the time of reporting. Extraoral examination did not reveal any abnormality. Intraoral examination revealed a dome-shaped, well-circumscribed swelling on the palatal region adjacent to maxillary left premolar and molar. The swelling extended mesiolaterally from maxillary left second premolar to second molar region and anteroposteriorly from left maxillary alveolus to the midpalatal region. The surface was smooth overall, except for a central ulceration. The ulcer showed yellowish necrotic slough and was surrounded by an erythematous halo (Fig. 1). On palpation, the swelling was nontender, nonfluctuant, soft to firm in consistency and adherent to the underlying structures.

Based on the clinical presentation, a provisional diagnosis of benign minor salivary gland tumor was made. A differential diagnosis of palatal abscess was also thought of but was ruled out considering the palpatory findings of the swelling.

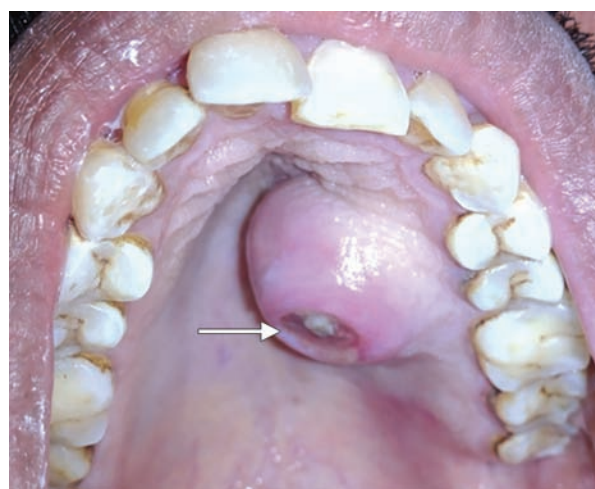


Fig. 1: Intraoral swelling with central traumatic ulceration (white arrow) seen on the hard palate

¹Senior Lecturer, ^{2,5,7}Reader, ^{3,6}Postgraduate Student (2nd Year)
⁴Professor

¹Department of Oral Medicine and Radiology, Aditya Dental College, Beed, Maharashtra, India

²⁻⁶Department of Oral Medicine and Radiology, M.A. Rangoonwala College of Dental Sciences and Research Centre Pune, Maharashtra, India

⁷Department of Oral Medicine and Radiology, Dr. D.Y. Patil Dental College and Hospital, Dr. D. Y. Patil Vidyapeeth, Pune Maharashtra, India

Corresponding Author: Nikhil Diwan, Reader, Department of Oral Medicine and Radiology, M.A. Rangoonwala College of Dental Sciences and Research Centre, Pune, Maharashtra India, Phone: +919422033652, e-mail: nikhil_diwan@yahoo.co.in

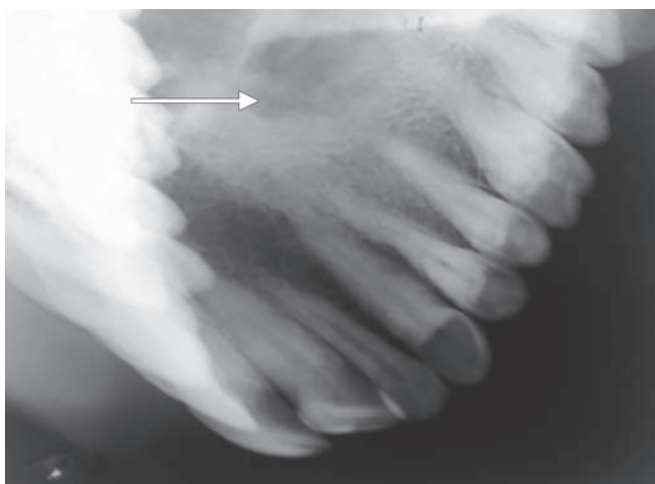


Fig. 2: Maxillary lateral occlusal radiograph showing soft tissue shadow with respect to the periapical region of 24, 25, and 26

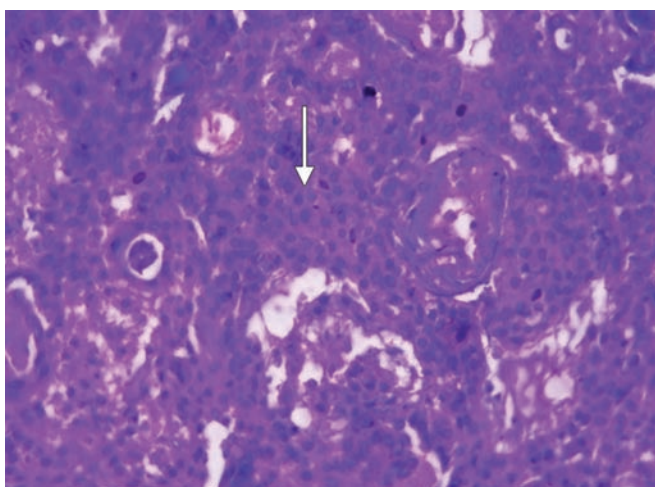
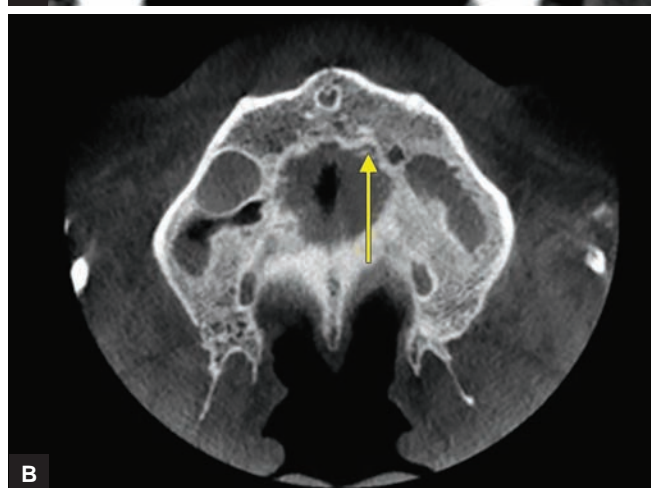
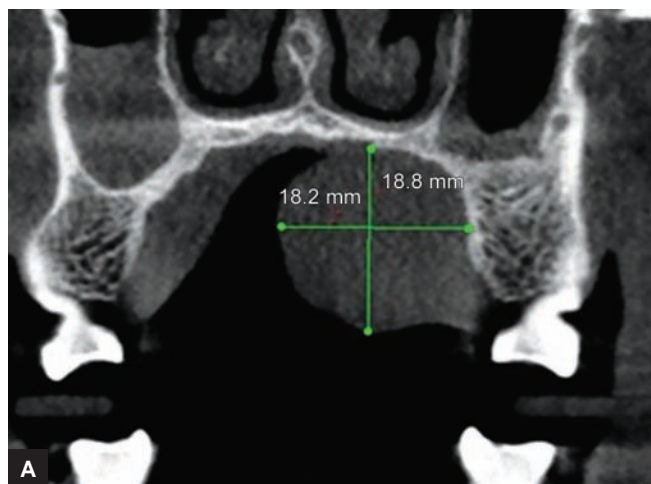


Fig. 4: Histopathological image (H & E, 4x) showing predominantly myoepithelial cells with numerous spindle cells (white arrow)

Maxillary lateral occlusal radiograph was made which showed soft tissue shadow below the periapical area of 24, 25, and 26 not contacting the teeth (Fig. 2). This was followed by cone beam computed tomography (CBCT) scan, which revealed soft tissue shadow showing as a hypodense swelling on the slope of hard palate of left side of size 18.6 × 18.8 mm in the coronal section (Fig. 3A). Cupped out resorption was seen on palatal cortex in axial section. No perforation of palate was observed (Fig. 3B).

Punch biopsy was taken and the histopathological report showed highly cellular lesion composed predominantly of MEC followed by spindle cells, a few clear cells, plasmacytoid cells, and a few duct like structures. The surrounding stromal tissue showed areas of hyalinization myxoid and focal chondroid differentiation (Fig. 4).

Based on these clinical and radiological features, a diagnosis of myoepithelioma of hard palate was made. The lesion was excised surgically (Figs 5A and B). The patient was provided with maxillary obturator (Fig. 6).

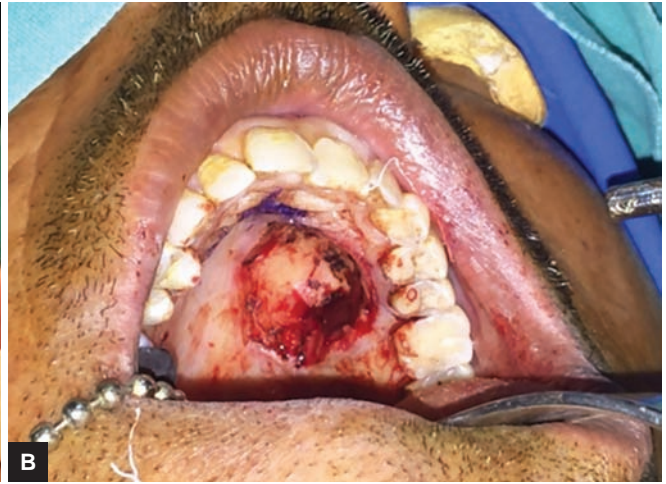
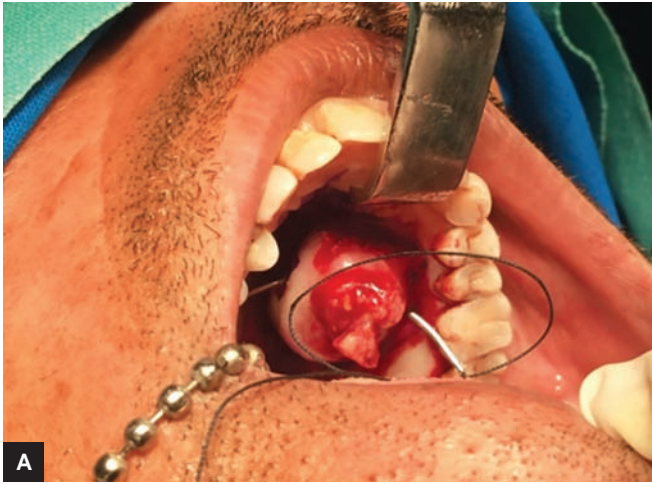
Figs 3A and B: Cone beam computed tomography image (coronal and axial section): (A) Note the extent of the lesion in the coronal section; and (B) cupped out resorption of palatal cortex could be noted in the axial section (yellow arrow)

Histopathological examination of the specimen confirmed the diagnosis of myoepithelioma of hard palate.

DISCUSSION

Myoepitheliomas are rare benign tumors of myoepithelial cell origin. These tumors are also reported in oral cavity, soft palate being the most common site of involvement. Earlier, these tumors were considered a variant of pleomorphic adenoma, however, now these were recognized as a histologically distinct entity by WHO in 1991.² The tumors present as asymptomatic, slowly progressive masses over a period of months to years. Myoepitheliomas present rare mitosis and absence of nuclear and cellular pleomorphism as well as a noninfiltrative growth typical of a benign tumor. The diagnosis of myoepithelioma is made based on history, physical examination, cytology, and histopathology. To determine the proper management regimen and treatment, an incisional biopsy must be performed. Plain film radiographs and CBCT scan can provide information on the location and size of the tumor and its extension to surrounding structures.



Figs 5A and B: Intra- and postsurgical images. Note the operating site after the excision of the mass, causing oroantral communication

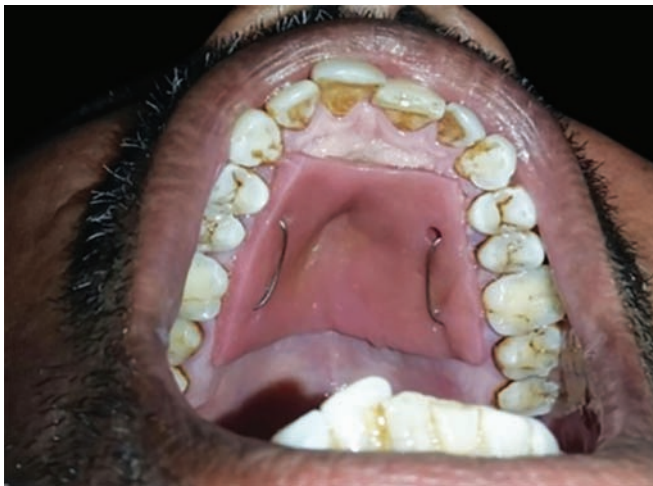

Fig. 6: Management of postsurgical defect with a maxillary obturator

The MEC are the normal constituents of major and minor salivary glands which are thin and spindle-shaped.³ It shows four different morphological patterns, which include nonmyxoid (solid), myxoid, reticular (canalicular), and mixed type.⁴ The cellular patterns of myoepithelioma consists of plasmacytoid cells, spindle cells (most common), epithelioid cells, and clear cells (least common) patterns. Plasmacytoid cells are distinguishable by their dense, nongranular or hyaline, abundant eosinophilic cytoplasm, whereas epithelioid cells are round to polygonal cells, with centrally located nuclei and a variable amount of eosinophilic cytoplasm.⁴ There are four subtypes of myoepithelioma depending in histologic features. They are spindle type, plasmacytoid, epithelioid, and clear-cell type.⁵ The treatment is wide local excision with the removal of periosteum or bone if they are involved.⁶ The other possible diagnosis of the lesion to be considered could be periodontal abscess, palatine tori, necrotizing sialometaplasia which is self-limiting and size of swelling will be less than 3 cm, fibrous hyperplasia, minor salivary gland tumors, such as pleomorphic adenoma, adenoid

cystic carcinoma which shows typical Swiss cheese pattern microscopically, low grade mucoepidermoid tumor which shows poorly defined ragged borders radiographically and which is usually a malignant.

Myoepitheliomas may be considered a variant of pleomorphic adenoma in which glanduloductal differentiation is entirely or virtually absent. It has been proposed that if the neoplasm contains <5% ductal and acinar components, it must be named myoepithelioma, and if there is ductal predominance, pleomorphic adenoma diagnosis should be established.⁷

Pleomorphic adenoma is considered to be the most common minor salivary gland constituting 40% of total cases consisting of epithelial and ductal cells in its tissue. Chondromyxoid matrix is seen in pleomorphic adenoma whereas it is absent in myoepithelioma and also there is absence of glanduloductal differentiation.^{8,9}

The recommended treatment for myoepithelioma is wide local excision with the removal of periosteum or bone if they are involved.⁶ These tumors do not present high levels of recurrence.

CONCLUSION

Myoepitheliomas are rare benign tumors presenting as slow growing asymptomatic masses. With thorough history, clinical examination, and radiological investigation, it should be carefully diagnosed and distinguished from the more common tumors, such as pleomorphic adenoma, adenoid cystic carcinoma.

REFERENCES

1. Chandra S, John S, Kiran B. Myoepithelioma of hard palate: a rare case report. *J Med Sci Health* 2015 Jan-Apr ;1(2):43-45.
2. Seifert, G.; Sobin, LH. Myoepithelioma. WHO international histological classification of tumours: histological typing of salivary gland tumours. 2nd ed. Berlin, Germany: Springer-Verlag; 1991. pp. 20-21.



3. Rastogi S, Modi M, Dhawan V, Kumar A. Myoepithelioma of palate—a case report and review of literature. *J Clin Diagn Res* 2008 Oct;2:1095-1099.
4. Sperandio FF, Giudice FS, Pinto-Junior Ddos S, de Sousa SC. Myoepithelioma of the soft palate: a case report giving special attention to the differential diagnosis. *J Oral Maxillofac Res* 2011 Apr 1;2(1):e4.
5. Zelaya FC, Rivera DQ, Vazquez JLT, Valencia CP, Cepeda LAG. Plasmacytoid myoepithelioma of the palate. report of one case and review of the literature. *Med Oral Patol Oral Cir Bucal* 2007 Dec 1;12(8):E552–E555.
6. Sreenivas SD. Pleomorphic adenoma of the palate – a case report. *J Indian Dent Assoc* 2011;5(4):557-558.
7. Swarna YM, Ali IM, Annigeri RG. A rare case report of plasmacytoid myoepithelioma of hard palate. *J Clin Case Rep* 2014 Feb;4(4):348.
8. Yadav AK, Nadarajah J, Chandrashekhara SH, Tambade VD, Acharya S. Myoepithelioma of the soft palate: a case report. *Case Rep Otolaryngol* 2013;2013:642806.
9. Ren J, Liu Z, Liu X, Li Y, Zhang X, Yang Y, Chen Y, Jiang S. Primary myoepithelial carcinoma of palate. *World J Surg Oncol* 2011 Sep 14;9:104.